

# Anatomic Factors Related to the Cause of Tennis Elbow

By Robert E. Bunata, MD, David S. Brown, MD, and Roderick Capelo, MD

*Investigation performed at the University of North Texas Health Science Center—John Peter Smith Affiliated Orthopedic Residency Program, Fort Worth, Texas*

**Background:** The pathogenesis of lateral epicondylitis remains unclear. Our purpose was to study the anatomy of the lateral aspect of the elbow under static and dynamic conditions in order to identify bone-to-tendon and tendon-to-tendon contact or rubbing that might cause abrasion of the tissues.

**Methods:** Eighty-five cadaveric elbows were examined to determine details related to the bone structure and musculotendinous origins. We identified the relative positions of the musculotendinous units and the underlying bone when the elbow was in different degrees of flexion. We also recorded the contact between the extensor carpi radialis brevis and the lateral edge of the capitellum as elbow motion occurred, and we sought to identify the areas of the capitellum and extensor carpi radialis brevis where contact occurs.

**Results:** The average site of origin of the extensor carpi radialis brevis on the humerus lay slightly medial and superior to the outer edge of the capitellum. As the elbow was extended, the undersurface of the extensor carpi radialis brevis rubbed against the lateral edge of the capitellum while the extensor carpi radialis longus compressed the brevis against the underlying bone.

**Conclusions:** The extensor carpi radialis brevis tendon has a unique anatomic location that makes its undersurface vulnerable to contact and abrasion against the lateral edge of the capitellum during elbow motion.

**Clinical Relevance:** This information may help us to understand the pathomechanics of lateral epicondylitis and provide a better rationale for operative and nonoperative treatment.

The pathogenesis of lateral epicondylitis (tennis elbow) remains unclear. Currently, the most popular theory is that the condition results from repeated contraction of the wrist extensor muscles—especially the extensor carpi radialis brevis—causing microscopic tendon tears that progress to the degenerative condition of tendinosis<sup>1-5</sup>. Attention has been directed primarily at internal stress from tension forces on the tendon<sup>3,6,7</sup>, with little research addressing the anatomic relationships between the extensor origins and the underlying osseous prominences at the elbow as a possible source of injury leading to tendon attrition and eventual rupture.

Several observations suggest that the anatomy and kinematics around the elbow might be important in the occurrence of tennis elbow. First, the pathological changes occur at a consistent location in the common extensor tendon origin

rather than at other locations along the tendon that are also under longitudinal internal stress<sup>1,5,7-11</sup>. Second, evidence suggests that healthy tendons do not rupture in their substance; instead, excessive tension causes either disruption at the musculotendinous junction or avulsion of a fragment of bone<sup>12</sup>. Third, the symptoms of tennis elbow can be elicited by elbow motion, specifically elbow extension, regardless of the position of the wrist<sup>10,11,13,14</sup>, or are more prominent with the elbow extended<sup>3,10,14,15</sup>. Finally, in addition to other effects, the preferred surgical procedures alleviate symptoms of tennis elbow by changing the structural arrangement of tendon and bone at the elbow by either cutting or excising portions of the extensor origin<sup>1,2,4,6,7,9,11,15,16</sup>.

The existing theories do not explain these observations; therefore, we examined elbow anatomy to see if interaction

**Disclosure:** The authors did not receive any outside funding or grants in support of their research for or preparation of this work. Neither they nor a member of their immediate families received payments or other benefits or a commitment or agreement to provide such benefits from a commercial entity. No commercial entity paid or directed, or agreed to pay or direct, any benefits to any research fund, foundation, division, center, clinical practice, or other charitable or nonprofit organization with which the authors, or a member of their immediate families, are affiliated or associated.

such as contact, rubbing, or pressure between tendons or between tendons and bone during elbow motion might contribute to the cause of lateral epicondylitis. In 1985, Briggs and Elliott<sup>17</sup> reported the findings of a static anatomical study of the origin of the extensor carpi radialis brevis. They concluded that “tennis elbow is primarily a mechanically-induced condition” and reported the tendon is “subject to shearing stress in all movements of the forearm, especially those involving power at the wrist.” We are not aware of other similar anatomic studies or studies of the dynamic relationship of the extensor carpi radialis brevis tendon to adjacent structures. However, attritional tendon damage elsewhere has been extensively studied<sup>12,18</sup>. We report our findings on the basic static anatomy of the lateral aspect of the elbow, the relationships of the structures at different positions of elbow flexion and extension, and the interaction (kinematics) of the structures during elbow motion.

## Materials and Methods

### Static Anatomy: Osteology

The Department of Anatomy and Cell Biology at the University of North Texas Health Science Center allowed us access to sixty embalmed (formalin perfusion plus immersion) cadavers. The cadavers were hermetically sealed in plastic bags and were stored at 44°F (6.7°C) until needed; they were then kept in stainless steel tanks at 65°F (18.3°C). No elbow had been previously dissected, and no elbow showed evidence of an old injury or surgery. The average age of the donors at the time of death had been 73.6 years (range, fifty-three to eighty-three years); thirty specimens were from male donors, and thirty were from female donors.

To determine the size and locations of bone prominences and tendon origins, we made two series of observations. First, we performed an indirect preliminary photographic study to understand more precisely the locations, sizes, and variations of bone and tendon anatomy. Next, we directly measured the same sizes and locations.

For the preliminary photographic study, we removed all of the soft tissue from twenty cadaveric humeri after etching and marking the origin of the extensor carpi radialis longus, the isolated origin of the extensor carpi radialis brevis, and the most prominent point of the lateral epicondyle. All dissections were done with use of 3.5-power loupe magnification and were performed from distal to proximal so that the individual muscles could be isolated. The humeri were stabilized in a frame holding a digital camera at fixed, reproducible orthogonal angles 33 cm (13 in) from the specimen, and pictures were made from directly anterior and directly lateral to the distal part of the humerus at 90°; each photograph was centered on the edges of the capitellum. A ruler was placed next to the humerus for each photograph to control for magnification. We used Adobe Photoshop Elements 2.0 software (Adobe Systems, San Jose, California) to analyze and measure the bone anatomy and the location of the tendon origins with use of the axes of the superior and lateral edges of the capitellum (see Appendix).

For the direct measurement study, forty additional el-

bows were dissected in the same way. We placed a transparent square on the superior and lateral edges of the capitellum and made measurements of the location of the same bone and tendon structures from those axes with use of an electronic caliper that was accurate to 0.1 mm (see Appendix).

### Positional Anatomy: Anatomic Relationships with Differing Elbow Positions

We studied the relationship of musculotendinous units to bone and to each other with the elbow at various positions of flexion (90°, 45°, 30°, and 0°). We observed and recorded the positional relationships of the capitellum, extensor carpi radialis longus, and extensor carpi radialis brevis under three conditions: with the extensor carpi radialis longus and extensor carpi radialis brevis together (Condition 1), with the extensor carpi radialis longus alone (Condition 2), and with the extensor carpi radialis brevis alone (Condition 3). A total of six cadaveric elbows were used. All six were used to observe Condition 1, and then the six elbows were divided into two groups of three elbows each. One of these groups was used for observation of Condition 2, and the other was used for observation of Condition 3. We prepared the extremities by removing the brachioradialis, extensor digitorum communis, extensor carpi ulnaris, and extensor digiti quinti proprius and by making a window in the elbow capsule over the capitellum. We left the extensor carpi radialis longus and extensor carpi radialis brevis attached to their humeral origins but cut their other soft-tissue attachments, including their distal insertions and all connections between them. The extensor carpi radialis longus and extensor carpi radialis brevis tendons were then replaced into the second dorsal wrist compartment and were placed under 6 lb (2.7 kg) of tension. Each extremity was mounted in a metal frame that fixed the humerus but allowed elbow motion. Mountings for a digital camera were fixed to the frame directly anterior and directly lateral to the distal part of the humerus. Photographs were made in the frontal and sagittal planes, 20 cm (8 in) from the specimen with the elbow at each selected position. To measure lateral tendon displacement, we placed reference marks on the capitellum and on the medial edge of the musculotendinous unit. The frontal photographs were analyzed for lateral movement relative to the mark on the capitellum, and the sagittal photographs were analyzed for evidence of bone and tendon contact and tendon distortion.

### Injection Study

To further examine the relationships at different elbow positions, we isolated and elevated the entire intact extensor mechanism to the humeral origin in three additional elbows. The musculotendinous units were not separated, so that the normal relationships would be maintained. We drilled a hole transversely across the distal part of the humerus, starting at the lateral surface of the proximal aspect of the capitellum and exiting through the medial epicondyle. A 2-mm cannula was passed through the hole and was left protruding medially but was placed flush with the capitellum laterally. The wrist exten-

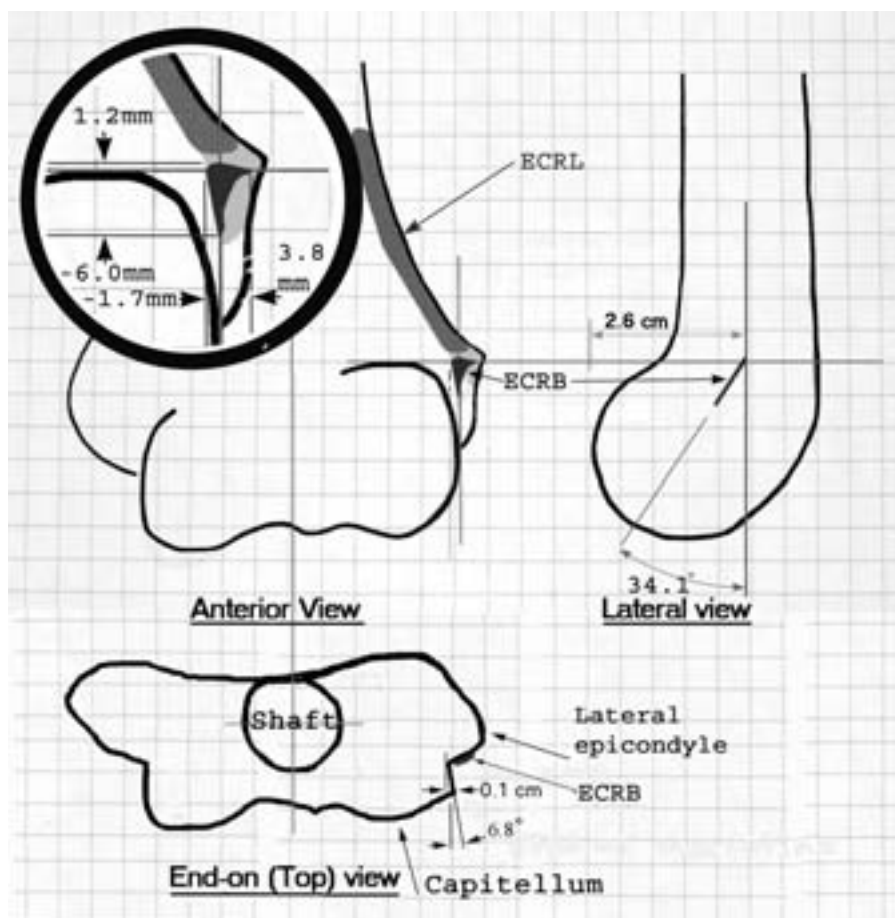


Fig. 1

Composite drawing of the distal part of the humerus, showing the average position of the extensor carpi radialis brevis origin in relation to the superior and the lateral edges of the capitellum. Shaded areas show musculotendinous origins. The lateral view shows the anterior placement of the capitellum, and the end-on view shows the protrusion of the lateral edge of the capitellum. The inset shows measurements of the average position of the extensor carpi radialis brevis (black shading) proximal and slightly medial to the lateral capitellum. (Grid = 0.5 cm.) ECRL = extensor carpi radialis longus, and ECRB = extensor carpi radialis brevis.

tor muscles were put back into the normal wrist compartments and were placed under tension. The elbow was then sequentially positioned at 90°, 45°, 30°, and 0° (full extension). At each stop, the undersurface of the extensor mechanism was marked with methylene blue dye using a 25-gauge 3.5-in (9-cm)-long needle that was introduced through the cannula. The extensors were held under 6 lb (2.7 kg) of tension throughout elbow motion and were allowed to follow their normal course. After the four injections were made, the extensor mechanisms were reflected and examined.

#### *Dynamic Anatomy: Tendon and Bone Relationships with Elbow Motion*

The positional studies confirmed contact between the tendons themselves and demonstrated tendon displacement and distortion from contact with bone, but the usual site of pathology—the underside of the conjoined tendon—could not be seen<sup>1,5,7,9-11</sup>.

In order to analyze the kinematics of the deep fibers of

the extensor carpi radialis brevis during elbow motion, we removed all extensor radial muscles and tendons, leaving just the elbow joint intact except for an anterior capsular window. A single size-0 nylon suture was used to represent the deep fibers of the extensor carpi radialis brevis, which could not be seen with the soft tissue intact. The suture was stretched from the medial aspect of the etched origin of the extensor carpi radialis brevis to the second compartment at the wrist and was kept under constant 0.7 kg of tension. The elbow was moved through a range of motion, and the kinematics of the suture was observed.

Initially, we used ten adult cadaver elbows; five were from male donors and five were from female donors, and five were from the left side and five were from the right side. A mark was placed on the capitellum, and another mark was placed on the suture, 1 cm distal to its emergence from the epicondyle. The elbow was then moved through a range of motion and was stopped at 90°, 75°, 60°, 45°, 30°, 15°, and full

extension. At each elbow position, the distance from the capitellar reference mark to the suture was measured with electronic calipers. The index point (designated 0 displacement) was defined as the measurement that was made with the elbow at 90° and the forearm in neutral rotation. Measurements were made in maximum supination, neutral, and maximum pronation (see Appendix).

Six additional cadaver elbows were used to perform the same observations with the capitellum intact and subsequently with the lateral third of the capitellum removed without jeopardizing elbow stability. The same measurements were made with use of these elbows but only in neutral rotation.

## Results

### Static Anatomy

#### Osseous Anatomy

In its distal fourth, the humeral shaft flattens and spreads to become spatula-shaped, making a base for the elbow joint and muscular attachments. The lateral flair of the bone from the shaft to the lateral condyle averaged 21.8° (range, 14° to 30°), resulting in the epicondyle being an average of 2.5 cm (range, 1.8 to 3.2 cm) lateral to the central axis of the humeral shaft. The distal part of the humerus tilted forward an average of 34.1° (range, 26.2° to 48°), which placed the anterior edge of the capitellum an average of 2.6 cm (range, 2.1 to 3.3 cm) anterior to the axis of the shaft and the muscle origins (Fig. 1).

We found the anatomical features of the distal part of

the humerus—the size and shape of the capitellum and lateral epicondyle and the locations of muscle origins—to be quite variable as indicated by the wide ranges in measured values. Figure 1 shows reference bone and tendon locations, with the inset detailing the extensor carpi radialis brevis origin measurements. From the anterior view, the lateral condyle (capitellum) approximated the shape of a hemisphere averaging 2.3 cm (range, 1.7 to 2.7 cm) in diameter. The epicondyle protruded an average of 4.8 mm (range, 0.7 to 8.7 mm) lateral to the outer edge of the capitellum at its widest point. The most prominent lateral projection—the most easily palpable point of the epicondyle—usually lay just proximal (average, 0.7 mm; range, -2.7 to 6.1 mm) to the proximal edge of the capitellum. As shown in Figure 1, when viewed from the lateral side, the anterior edge of the capitellum was an average of 2.6 cm (range, 2.1 to 3.3 cm) anterior to the lateral humeral axis. When viewed end-on, along the axis of the humerus (Fig. 1), the lateral edge of the capitellum flared from its base to protrude an average of 1 mm (range, 0 to 4.6 mm), or 6.8° (range, 0° to 18°). These observations demonstrate that much of the lateral epicondyle is medial and posterior to the outer, anterior edge of the capitellum.

#### Musculotendinous Anatomy

The muscles of the lateral aspect of the elbow are the brachioradialis, extensor carpi radialis longus, extensor carpi radialis brevis, extensor digitorum communis, extensor carpi ulnaris,

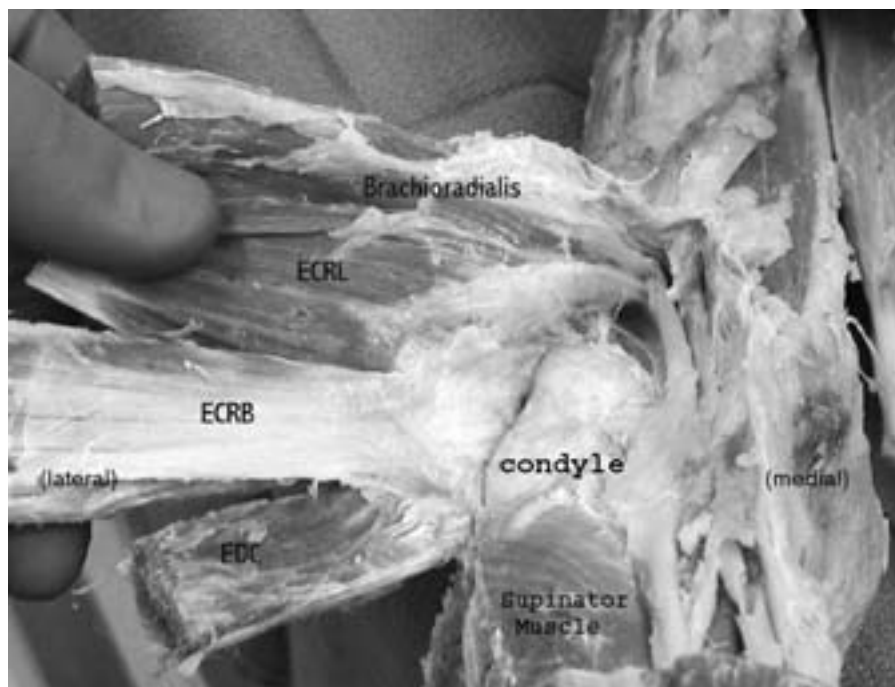


Fig. 2

The extensor mechanism could be reflected without separation of its components. All tendons were noted to blend into one fascial sheet at the elbow. This sheet slides against the capitellum during elbow motion, and the extensor carpi radialis brevis is in a vulnerable position within the sheet. ECRL = extensor carpi radialis longus, ECRB = extensor carpi radialis brevis, and EDC = extensor digitorum communis.

and supinator. The extensor carpi radialis brevis, extensor digitorum communis, and extensor carpi ulnaris were seen to attach to the humerus together as a strong, identifiable conjoined tendon. The extensor digiti quinti proprius blended with the extensor digitorum communis in the forearm and was difficult to distinguish within the conjoined tendon. All of these structures—the brachioradialis, extensor carpi radialis longus, conjoined tendon, and supinator—blended together at the elbow and attached to the humerus as a merged extensor mechanism (Fig. 2). These structures are distinct only in the forearm<sup>10,14,19,20</sup>.

The extensor carpi radialis longus and the extensor carpi radialis brevis were intimately blended and could not be distinguished from one another in the proximal part of the forearm; however, if the musculotendinous units were separated in the distal part of the forearm, the separation could be extended proximally to the elbow if done with care and the use of magnification. Along the inferior edge of the extensor carpi radialis longus, there was a 3 to 5-mm-wide fascial band enclosing it and providing continuous attachments for the fusiform, bitendinous extensor carpi radialis brevis. The line of separation usually led directly to the most prominent point of the epicondyle.

The extensor carpi radialis longus attached along the supracondylar ridge as a muscle<sup>14</sup>, without tendon intervening between it and bone. The distal extent of its insertion averaged 0.6 cm (range, 0 to 1.3 cm) proximal to the superior edge of the capitellum. The muscle then extended proximally an average of 3.5 cm (range, 2.3 to 5.3 cm) so that its body lay in an area directly proximal to the capitellum. When viewed laterally, the extensor carpi radialis longus origin was seen to be in line with the longitudinal axis of the humerus. This put the extensor carpi radialis longus origin posterior and medial to the epicondyle, the capitellum, and the extensor carpi radialis brevis origin.

The origin of the extensor carpi radialis brevis was one of our most interesting findings. The purely tendinous<sup>14</sup> extensor carpi radialis brevis attachment lay deep and superior within the stout tendon shared with the extensor digitorum communis and extensor carpi ulnaris. This arrangement placed the extensor carpi radialis brevis adjacent to the capitellum and covered by the extensor digitorum communis tendon in addition to the extensor carpi radialis longus muscle mentioned above.

We measured the location of the extensor carpi radialis brevis origin (Fig. 1, inset) in relation to the lateral and superior margins of the capitellum. In relation to the lateral margin of the capitellum, we found the medial edge of the extensor carpi radialis brevis to lie an average of 1.7 mm medial (range, 5.9 mm medial to 1.2 mm lateral) to the outer edge of the capitellum; its lateral edge averaged 3.8 mm (range, 0.8 to 6.3 mm) laterally. The medial aspect of the extensor carpi radialis brevis insertion was medial to the outer edge of the capitellum in thirty-two of the forty directly measured specimens.

The proximal edge of the extensor carpi radialis brevis was an average of 1.2 mm proximal to the superior margin of the capitellum (range, 3.7 mm distal to the superior margin to 8.0 mm proximal to the superior margin). The distal extent of the extensor carpi radialis brevis origin was an average of 6 mm distal to the superior margin of the capitellum (range, 12.9 distal to the superior margin to 10.4 mm proximal to the superior margin). The most distal extent of the extensor carpi radialis brevis origin was never more distal than the middle of the capitellum and usually was well proximal to the middle of the capitellum (the site of the collateral ligament attachment).

#### Positional Anatomy

##### Extensor Carpi Radialis Longus and Extensor Carpi Radialis Brevis Together (Fig. 3)

With the elbow in 90° of flexion, the extensor carpi radialis longus and extensor carpi radialis brevis took a straight-line course from their humeral attachments to the second dorsal wrist compartment. There was no contact with the elbow, and the extensor carpi radialis longus and extensor carpi radialis brevis lay adjacent to each other. With the elbow in 45° of flexion, the muscle showed evidence of contact with the underlying structures. The muscle flattened when viewed anteriorly and bowed when viewed laterally. As extension continued, the medial edge of the extensor carpi radialis longus pressed more firmly on the condyle and was pushed laterally. In the set of six observations involving both musculotendinous units, the extensor carpi radialis longus moved an average of 6 mm laterally when the elbow moved from flexion to full extension. When viewed laterally, the extensor carpi radialis longus and the extensor carpi radialis brevis bowed over the capitellum and epicondyle as extension progressed. With further extension, the extensor carpi radialis longus stretched over, covered,

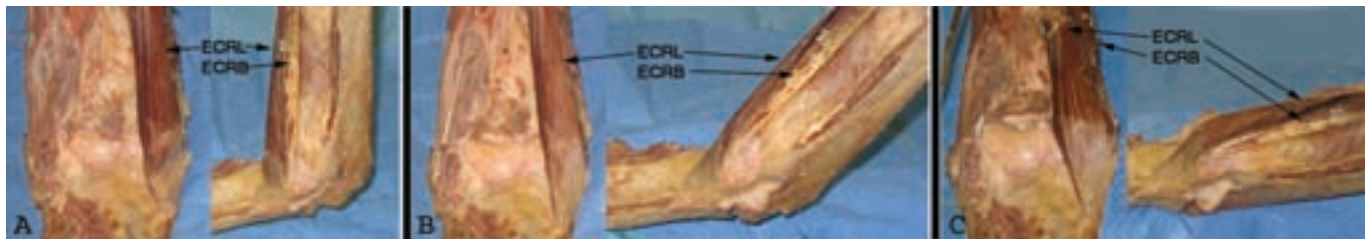

Fig. 3

Anteroposterior and lateral photographs of the distal part of the humerus, showing the relationships of the extensor carpi radialis longus (ECRL) (muscle) and the extensor carpi radialis brevis (ECRB) (tendon) at 90°, 45°, and full extension. The extensor carpi radialis longus is stretched, covering the extensor carpi radialis brevis and the underlying bone.

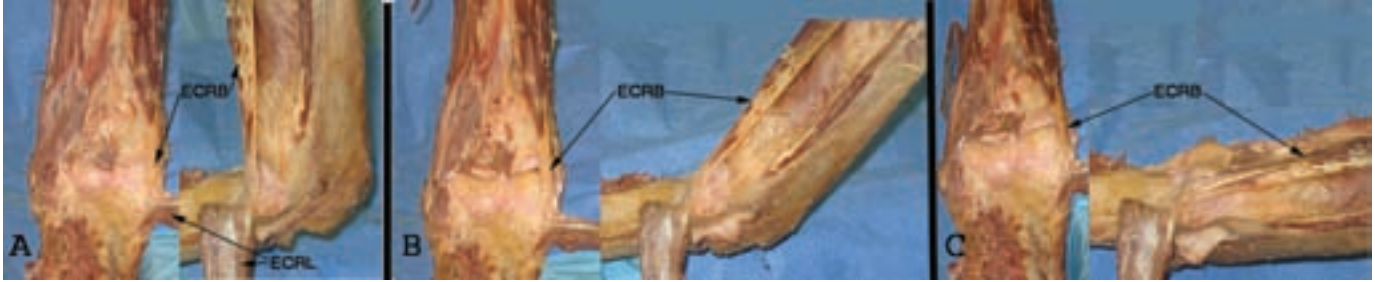

Fig. 4

Anteroposterior and lateral photographs of the distal part of the humerus, showing the extensor carpi radialis brevis (ECRB) alone at 90°, 45°, and full extension (the extensor carpi radialis longus [ECRL] has been reflected). The tendon lies on the capitellum and then slips lateral to it. Comparison of the position of the extensor carpi radialis brevis in the anterior view in Figure 4, A with that in Figure 4, C reveals the lateral displacement that occurs with elbow extension.

and hid the proximal aspect of the extensor carpi radialis brevis tendon in all specimens. We interpreted the bowing and stretching of the extensor carpi radialis longus muscle as an indication that it pressed on the underlying extensor carpi radialis brevis and capitellum, thereby potentially increasing the abrasive forces.

#### Extensor Carpi Radialis Brevis Alone (Fig. 4)

When the extensor carpi radialis longus was removed, the isolated extensor carpi radialis brevis could be seen through the entire course of elbow motion. At 90° of elbow flexion, it ran a straight course from the humerus to the wrist, lying superior and lateral to the condyle. As extension progressed, the tendon was positioned between the point of the epicondyle and the

lateral edge of the condyle, sliding against and being pushed laterally by the capitellum by 1, 2, and 6 mm in our three specimens. When viewed from the side, at full extension, the extensor carpi radialis brevis stretched and bowed notably over the condyle and then, after sliding laterally, it bowed over the epicondyle.

#### Injection Study

With the end of the cannula lying at the edge of the lateral aspect of the capitellum, the four injections formed a line transverse to the direction of the conjoined tendon fibers, 1 to 1.5 cm long on the underside of the muscle unit, approximately 1 cm from the tendon attachment to the humerus (Fig. 5). After the injections, we separated the tendons to identify which part

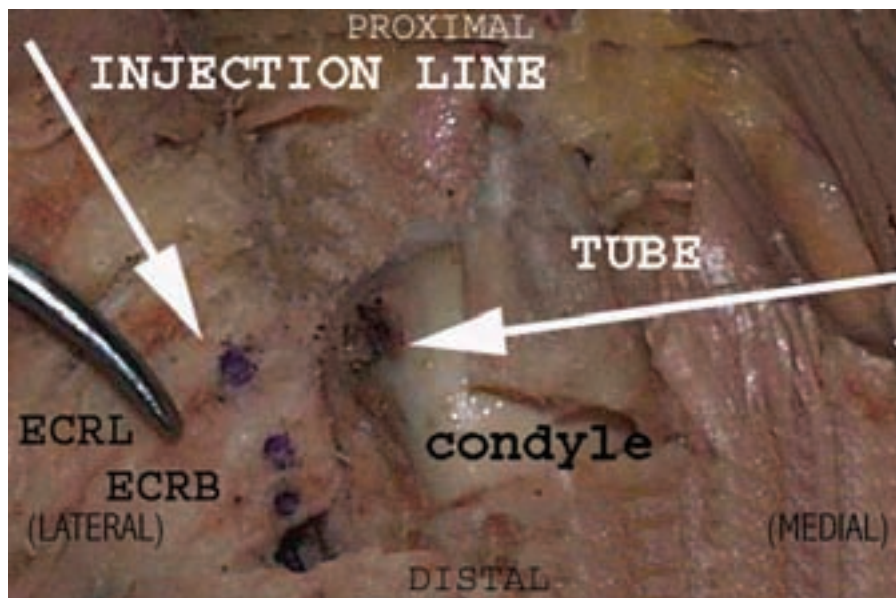


Fig. 5

Close-up view of extensor mechanism and humeral condyle. Left arrow points along the line of dye injections made at 90°, 45°, 30°, and 0°. The injections were made through a cannula exiting the lateral edge of the capitellum, shown by the right arrow. The line shows where the lateral edge of the capitellum contacted the overlying extensor carpi radialis brevis (ECRB) and extensor carpi radialis longus (ECRL). This figure can be compared with Figure 2, which shows the entire extensor mechanism intact.

**TABLE I Suture Displacement Resulting from Capitellum Contact\***

	Elbow Position in Degrees of Flexion						
	90°	75°	60°	45°	30°	15°	0°
Supination (mm)	1.2	1.4	1.8	2.2	2.7	3.3	3.6
Neutral (mm)	0 (index)	0.6	1.3	2.1	2.4	2.8	3.4
Pronation (mm)	-1.1	-0.1	0.7	1.6	2.3	2.7	3.2

\*Average suture movement caused by contact with capitellum as the elbow moved from 90° of flexion to full extension with the forearm in three positions of rotation. The zero (index) position was defined as distance from the markers with the elbow at 90° flexion and the forearm in neutral rotation. With elbow in flexion, the suture at the capitellum contact point moves laterally with supination and medially with pronation, resulting in different starting points.

of the extensor mechanism passed the capitellum during elbow motion. In all three specimens, the dye was injected into the extensor carpi radialis brevis tendon; however, in two specimens, the dye that was injected when the elbow was in full extension stained some fibers of the extensor carpi radialis longus.

#### Dynamic Anatomy (Fig. 6 and Appendix)

In all ten elbows that were included in the initial dynamic study, the suture contacted the lateral edge of the capitellum at 75° of elbow flexion and was displaced laterally because of this contact with the capitellum, with more than half of the suture displacement occurring in the first 45° of elbow extension. Contact area and suture displacement varied between cadavers as shown by the ranges of measurements. The capitellum displaced the suture laterally by an average of 3.4 mm (range, 2 to 6.4 mm) when the forearm was in neutral rotation. The total amount of displacement was less with the forearm in supination (average, 2.4 mm; range, 1.1 to 5.2 mm) and more with the forearm in pronation (average, 4.3 mm; range, 1.8 to 8.7 mm) (Table I). When the capitellum was partially resected, the suture was no longer displaced as far laterally as it was with the capitellum intact. The final suture displacement without the capitellum averaged 1.3 mm (range, 0 to 2.1 mm). The suture displacement occurring in these specimens during the final 30° of extension was due to contact with the radial head and forearm muscles.

In the first ten elbows that were examined with a suture

representing the extensor carpi radialis brevis, the suture stayed in contact with the capitellum throughout the range of motion tested. In the second set of six elbows, we found that the suture did not maintain contact in three elbows. In two of these elbows, the suture was lifted off the capitellum as the elbow reached full extension because of contact with the radial head or part of the supinator muscle covering the neck of the radius, once at 45° and once at 30°. In the third elbow, the suture did not touch the capitellum at all in neutral rotation because the extensor carpi radialis brevis origin was lateral to the capitellum and the elbow was in valgus; in this elbow, the suture contacted the capitellum starting at 65° when the forearm was in pronation.

Once we demonstrated rubbing of the suture against bone, we made videos of the suture contacting, being displaced laterally, and rubbing against the capitellum. This is by far the most dramatic and convincing evidence that extensor carpi radialis brevis abrades against the capitellum during elbow motion (see Appendix).

#### Discussion

We believe that our observations of the anatomy of the lateral aspect of the elbow show that commonly there is considerable contact between the undersurface of the extensor carpi radialis brevis and the lateral edge of the capitellum. We also believe that this contact might be a factor leading to the tendon injury called “tennis elbow,” or lateral epicondylitis.

In our static anatomic study, the muscle and tendon ori-

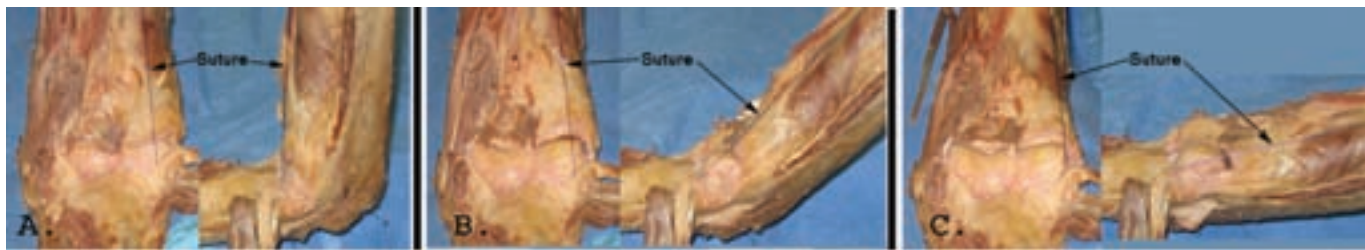

Fig. 6

Suture (labeled) stretched from the most medial origin of the extensor carpi radialis brevis to the second dorsal compartment, showing contact of the suture with the lateral aspect of the capitellum with the elbow at 90°, 45°, and full extension. The suture behaves as the extensor carpi radialis brevis does as shown in Figure 4.

gins were found to lie posterior and medial to the prominences of the distal part of the humerus, meaning that with elbow extension the muscles and tendons will contact and abrade against bone. The extensor carpi radialis brevis tendon, being the deepest part of the extensor mechanism and lying proximal and slightly medial to the protruding capitellum, is in a position to be particularly subject to abrasion. The static anatomy observations also showed that there is a great deal of variation in the size and shape of the capitellum and in the location of the tendon origins. These variations, of which we believe the location of the extensor carpi radialis brevis to be the most important, may explain why tendon injury develops in some people and not others.

The most common yet vague description of the site of damage in tennis elbow is stated to be the origin of the extensor carpi radialis brevis. This has been reported by some to be the junction of tendon with bone<sup>4</sup>, but more descriptions and illustrations in the literature place the injury in the proximal segment of the extensor carpi radialis brevis and the adjacent tendons<sup>1,5-11,14</sup>. In the present study, injection markings on the undersurface of the extensor mechanism indicated that the extensor mechanism slides transversely against the lateral edge of the capitellum as the elbow extends and flexes. These marks identified which part of the extensor mechanism opposes the capitellum. They were approximately 1 cm distal to the extensor origin and corresponded with the most commonly described location of damage in patients with tennis elbow. The markings were primarily in the extensor carpi radialis brevis but also into some fibers of the extensor carpi radialis longus. We conclude that the structures involved in contact and wear are the extensor mechanism (specifically, the extensor carpi radialis brevis, 1 cm distal to its osseous origin) and the lateral edge of the capitellum, and we believe that this wear leads to tendon abrasion as an initial step in the cause of tennis elbow.


Dramatic bowing and stretching of the tendons over the epicondyle and the capitellum occur with the elbow in full extension. It is unclear whether this tension plays a role in augmenting tendon damage; however, it may be the reason that pain often increases with elbow extension.

Having shown that the extensor carpi radialis brevis rubs on the lateral condyle during elbow motion leaves the question of how this relates to tennis elbow. As tendons can withstand tensile forces larger than can be exerted by their muscles or sustained by bone<sup>12</sup>, tendon rupture suggests that there is preexisting pathology before mechanical overload can result in tearing of the tendon<sup>12,18</sup>. The wear or abrasion of the proximal 1 to 2 cm of the extensor carpi radialis brevis resulting from rubbing on the lateral condyle could cause attritional damage.

While our study was undertaken solely to identify possible anatomic relationships that might contribute to the cause of tennis elbow, it might also have implications for the surgical treatment of this condition. If tennis elbow is, in fact, a developing or impending attritional tendon rupture, then relieving this contact seems to be the logical treatment. The easiest way to accomplish this would be to cut and/or excise those soft tissues rubbing on bone—the extensor carpi radialis brevis, the distal fascia of the extensor carpi radialis longus, and part of the extensor digitorum communis. Tendon release from the humerus distal to the proximal third of the capitellum is probably not needed, and the lateral ligament must be protected<sup>17,14,19,21</sup>. There is good evidence that the extensor carpi radialis brevis gets adequate support from extensive fascial attachment to prevent its retraction distally<sup>5,9,19,22</sup> and that proximal release is safe. This proposal is in agreement with the abundance of favorable results obtained in association with both open and arthroscopic procedures to detach and realign the extensor origin<sup>1,2,4,6,7,9,15</sup>. Failure to release or excise an adequate amount of tissue to relieve all abrasion may explain the failure of some surgical procedures.

We agree with Briggs and Elliott<sup>17</sup> that tennis elbow is a mechanically induced condition. However, we believe that tendon injury resulting from lateral abrasion against bone during elbow motion is an important factor in its cause. This injury under the stress of longitudinal tension leads to tearing of the tendon as seen in other attritional tendon ruptures. Hopefully this anatomic study will lead to more effective treatment and prevention of this painful and disabling condition.

### Appendix

 Photographs showing the experimental setup are available with the electronic versions of this article, on our web site at [jbjs.org](http://jbjs.org) (go to the article citation and click on "Supplementary Material") and on our quarterly CD-ROM (call our subscription department, at 781-449-9780, to order the CD-ROM). A video demonstrating the extensor carpi radialis brevis rubbing on the capitellum is also available on our web site. ■

NOTE: The authors thank the members of the Department of Anatomy and Cell Biology at the University of North Texas Health Science Center at Fort Worth, Texas, for their assistance with this project.

Robert E. Bunata, MD  
4054 Hildring Drive West, Fort Worth, TX 76109. E-mail address:  
[rbunata@hsc.unt.edu](mailto:rbunata@hsc.unt.edu)

David S. Brown, MD  
Roderick Capelo, MD  
2020 West Highway 114, Suite 110, Grapevine, TX 76051

### References

1. Almekinders LC. Tendinitis and other chronic tendinopathies. *J Am Acad Orthop Surg.* 1998;6:157-64.
2. Coonrad RW, Hooper WR. Tennis elbow: its course, natural history, conservative and surgical management. *J Bone Joint Surg Am.* 1973;55:1177-82.
3. Kraushaar BS, Nirschl RP. Tendinosis of the elbow (tennis elbow). Clinical features and findings of histological, immunohistochemical, and electron microscopy studies. *J Bone Joint Surg Am.* 1999;81:259-78.
4. Putnam MD, Cohen M. Painful conditions around the elbow. *Orthop Clin North Am.* 1999;30:109-18.
5. Nirschl RP. Sports and overuse injuries to the elbow. Muscle and tendon



trauma. In: Morrey BF, editor. *The elbow and its disorders*. 2nd ed. Philadelphia: W.B. Saunders; 1993. p 537-52.

6. Nirschl RP. Tennis elbow. *Orthop Clin North Am*. 1973;4:787-800.

7. Cohen MS, Romeo AA. Lateral epicondylitis: open and arthroscopic treatment. *J Am Soc Surg Hand*. 2001;1:172-6.

8. Owens BD, Murphy KP, Kuklo TR. Arthroscopic release for lateral epicondylitis. *Arthroscopy*. 2001;17:582-7.

9. Nirschl RP, Pettrone FA. Tennis elbow. The surgical treatment of lateral epicondylitis. *J Bone Joint Surg Am*. 1979;61:832-9.

10. Ciccotti MG, Lombard SJ. Lateral and medial epicondylitis of the elbow. In: Jobe FW, editor. *Operative techniques in upper extremity sports injuries*. St. Louis: Mosby; 1996. p 431-46.

11. Cabot A. Tennis elbow, a curable affliction. *Orthop Rev*. 1987;16:69-73.

12. Woo SL-Y, An K-N, Frank CB, Livesay GA, Ma CB, Zeminski J, Wayne JS, Myers BS. Anatomy, biology, and biomechanics of tendon and ligament. In: Buckwalter JA, Einhorn TA, Simon SR, editors. *Orthopaedic basic science: biology and biomechanics of the musculoskeletal system*. 2nd ed. Rosemont, IL: American Academy of Orthopaedic Surgeons; 2000. p 581-616.

13. Gardner RC. Tennis elbow: diagnosis, pathology and treatment. Nine severe cases treated by a new reconstructive operation. *Clin Orthop Relat Res*. 1970;72:248-53.

14. Boyer MI, Hastings H 2nd. Lateral tennis elbow: "Is there any science out there?". *J Shoulder Elbow Surg*. 1999;8:481-91.

15. Verhaar J, Walenkamp G, Kester A, van Mameren H, van der Linden T. Lateral extensor release for tennis elbow. A prospective long-term follow-up study. *J Bone Joint Surg Am*. 1993;75:1034-43.

16. Yergler B, Turner T. Percutaneous extensor tenotomy for chronic tennis elbow: an office procedure. *Orthopedics*. 1985;8:1261-3.

17. Briggs CA, Elliott BG. Lateral epicondylitis. A review of structures associated with tennis elbow. *Anat Clin*. 1985;7:149-53.

18. Kannus P, Jozsa L. Histopathological changes preceding spontaneous rupture of a tendon. A controlled study of 891 patients. *J Bone Joint Surg Am*. 1991;73:1507-25.

19. Jordan SE. Surgical anatomy of the elbow. In: Jobe FW, editor. *Operative techniques in upper extremity sports injuries*. St. Louis: Mosby; 1996. p 402-10.

20. Morrey BF. Anatomy of the elbow joint. In: Morrey BF, editor. *The elbow and its disorders*. 2nd ed. Philadelphia: W.B. Saunders; 1993. p 29-32.

21. Morrey BF. Surgical failure of the tennis elbow. In: Morrey BF, editor. *The elbow and its disorders*. 2nd ed. Philadelphia: W.B. Saunders; 1993. p 553-9.

22. Gray H. Muscles and fascia of the forearm. In: Goss CM, editor. *Anatomy of the human body*. 27th ed. Philadelphia: Lea and Febiger; 1959. p 506.